

PAPER • OPEN ACCESS

Clinical and radiological assessment of the effect of low level laser therapy on delayed bone fractures healing

To cite this article: Osama Al Balah *et al* 2020 *J. Phys.: Conf. Ser.* **1472** 012002

View the [article online](#) for updates and enhancements.



IOP | ebooks™

Bringing you innovative digital publishing with leading voices to create your essential collection of books in STEM research.

Start exploring the collection - download the first chapter of every title for free.

Clinical and radiological assessment of the effect of low level laser therapy on delayed bone fractures healing

Osama Al Balah¹, Ahmad Allam², Ghada Aid¹, Eslam Tabl², Alaaeldin Abdelfatah^{1,*}

¹National Institute of Laser Enhanced Sciences, Cairo university

²Faculty of medicine, Banha University.

* Correspondence: alaaeldin48@yahoo.com; Tel.: +201229798348

Abstract: Low level laser has been conducted for treatment of bone fracture on animal and had shown positive results. If laser energy is delivered at optimal dose with appropriate parameters ,it might get best results however a little research in the literature has conducted on the effect of low level laser on human bone fracture. The aim of the study was to assess the radiological and clinical difference of the effect of low level laser therapy on the delayed bone healing of patients with different bone fractures. This was a prospective study conducted in Benha university hospital on 33 patients with delayed and non-union of bone fractures via low level laser diode laser with a wavelength 905nm. There were 27 male 5 female patients, mean age group ± 34.43 range (24 years to 67 years) ,the mean delayed of union was $\pm 6,68$ range (3 months to 15 months). At the end of the study, union is achieved in mean period $\pm 1,7$ (1 month to 4,1 month)which led to success of about 70% improvement of the treated group ,union mean number of sessions used $\pm 23,375$ (range 15 sessions to 50 sessions) , Mean Visual Analog Scale (VAS) $\pm 1,3$ range from (0 to 6). the present study indicate that Low level laser therapy is an effective modality for treatment of delayed bone fracture ,can relieve pain and increase range of motion of the associated stiff joints with no adverse effect provided that adequate patient selection has conducted.

Keywords: Low level laser, Delayed union, non-union, Bone healing, Fracture.

1. Introduction

The introduction Fractures are the most common traumatic injuries to humans. The repair of bone fractures is considered to be a regenerative process as it usually restores the damaged bone tissue to its pre-injury status with its cellular composition, structure and biomechanical function. However the highly regenerative capacity of bone there is about 10% of fractures that may fail to heal normally(**Einhorn & Gerstenfeld, 2015**).

Around 10 to 15% of annual fractures in the united states end up with delayed union or nonunion with a high incidence of impaired fracture healing (**Bahney et al., 2015**).

There are a lot of factors that could result in delayed union and non-union status in bone repair process. These factors could include fracture displacement; sever injury to the surrounding soft tissue and infection at the fracture site. Factors such as medications could impair the healing process. Patient, himself could be a factor as age, smoking and nutritional status could affect the process of healing of fracture (**Phieffer & Goulet JA., 2006**).

Delayed and un-union had been a big problem so scientists have started to search for a new modality to enhance the healing of delayed bone fracture such as physical modality. Early studies on physical modalities as mean of bone healing was performed by Yasuda, who published his work on the piezoelectric forces within bone (**Yasuda., 1953**).



Physical modalities used for enhancement of bone healing like electromagnetic field (**Griffi et al., 2011**), low intensity pulsed ultrasound (LLPUS) (**Watanabe et al., 2010**) and Electric stimulation (**Griffin et al., 2011**).

Low-level laser therapy (LLLT) has been investigated as a new physical modality that could influence the cellular activity through photophysical, photochemical and photobiological mechanisms that had different effects on the irradiated cell (**Karu T., 1989**). Low level laser therapy has been shown to modulate inflammation, accelerate cell proliferation and enhance healing of various tissue (**Ueda Y&Shimizu N 2001**).

The conflicting of results regarding the use of LLLT as a biostimulatory are suggested to be related to different parameters which used in the treatment like wavelength, treatment dose, power density and the frequency of application of LLLT treatment (**Pinheiro AL &Gerbi ME .,2006**).

Many studies have introduced the clinical effect of using LLLT as a modality for stimulating the healing process of bone fracture. These studies have a variable outcomes with different parameters used in treatment procedures which explain the diversity of result among the research protocols. Up till now there is no known accepted parameters for the use of LLLT as a stimulus for bone healing (**Ebrahimi et al., 2012**).

Low level laser therapy LLLT has been introduced for treatment of fractures in experimental models (**Shakouri et al., 2010**). It was found that LLLT when administered for short duration of time had promoted the proliferation and differentiation of human osteoblasts as compared to non-irradiated cells (**Liebert, 2005**). In a meta-analysis performed by (**Tajali et al., 2010**) showing that LLLT has improved fracture healing in animal.

A human double blind based study administered LLLT with 830nm wavelength for the treatment of closed bone fractures of wrist and hand and found that LLLT has a stimulatory effect on bone healing relieving of pain and had improved the hand function (**Hui-ju et al., 2017**).

2-Materials and methods

After approval of the Laser Institute Research Ethical Committee, National Institute of Laser Enhanced Sciences (N.I.L.E.S) Cairo University the present study was carried out in the department of orthopedic surgery at Benha university hospital, Benha, Cairo, Egypt. 33 patients were diagnosed as delayed and non-union bone fractures with different fracture sites were recruited from the outpatient clinic and referred to the orthopedic surgery department. The orthopedic surgeon had cleared that all patients are free from microbial infection such as active osteomyelitis, tumors or open wounds at the site of delayed fracture healing.

The clinical research protocol was approved by the ethical committee of Benha university hospital. All the patient met the criteria of inclusion:

- (1) Delayed and non-union bone fractures;
- (2) No medical treatment nor physical therapy was introduced for patients;
- (3) Patients are instructed to follow their life pattern as usual.

All patients were informed with all the details of the study procedures, laser therapy effects and its applications in musculoskeletal disorders. All patients gave informed consent for LLLT treatment for their cases. Patients were recruited between June 2015 and February 2019. During the study, patients were informed to avoid taking any anti-inflammatory drugs or supplements. Other treatments, such as physical therapy or active exercise were not allowed during the course of treatment.

3- Study design

The participant were assigned to receive LLLT, a laser device (905nm) was used to emit a laser energy 3 times per week for 2 months using an infrared pulsed laser Giotto LED SPA 2003 made in Italy (Fig. 1): wavelength 905 nm, spot size diameter of 5 mm, frequency 10000 Hz, average power 12 W, energy of 4 J and pulse width of 100 ns and area = 0.2 cm². The research was done after ethical approval from the Institute committee and the Benha university hospital , All participant read, approved, and signed informed consent.

Clinical assessments were performed for pain, edema ,range of motion. Radiographic assessment were performed prior the start of treatment to determine the potential suitable sites for exposure to the laser treatment and to be the reference for the follow up of the efficacy of the laser treatment protocol, another radiographic assessment performed at the end of the course of treatment to assess the outcome of LLLT treatment.

4-Procedure

The physical therapist and the patient wear a protective eye goggles to avoid any harmful effect of the laser device or any reflection from the surrounding surfaces. The area of each fracture site was irradiated using a treatment dose of 12J/cm². The laser device was equipped with a timer, which monitored and automatically turned off the power after end of treatment by which an audible signal was issued to alert the participant and the physical therapist that the treatment session had ended and there is a reflective red light at the end of prop to determine the spontaneous emission of the infrared laser or that the device is not emitting any laser. The laser prop was applied with a direct contact to the skin over the fracture site, 1 cm above and 1 cm below the fracture site once a day, 3 days a week. Each treatment course lasted 2 months, ensuring that the input dose was sent into the unit area.

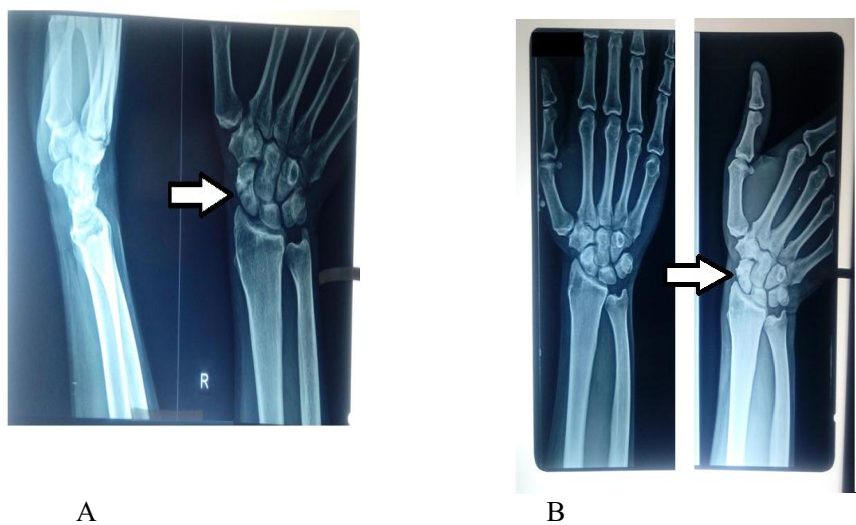


Fig. 1 Giotto MED SPA laser with protective eye goggle

5-Assessments

5.1-Radiographic signs of bone healing.

Radiographic evaluation was done by the orthopedic surgeon, who reviewed the X-rays for evidence of delayed and non-union fracture healing. Antero-posterior and lateral views of the fracture site were examined and the same X-rays were reviewed by an independent surgeon. The identity of the patient, the treating surgeon and the facility were blinded. Clinical and radiographic evaluation took place prior to laser treatment and at the end of LLLT treatment protocol (figure 2&3). In our clinical study the endpoint was to establish efficiency by pre- and post-treatment comparison of physical examinations and radiographic reviews for each patient. For the assessment of fracture repair, the radiographic signs of bone healing were evaluated using two parameters, the first parameter was a detectable cortical bridging or callus formation over the bone cortex, the second parameter is the gradual disappearance of the interruption of the cortex at the fracture site which is considered the fracture line. This assessment of radiological healing is in accordance radiographic union score for tibia (RUST), which was used as assessment tool and it has been to show an increase agreement among surgeons and radiologists in assessing fracture repair (Kooistra et al., 2010).



As shown in figure 2 (A: x-ray of fracture of right scaphoid before laser treatment and B: after the course of laser treatment)

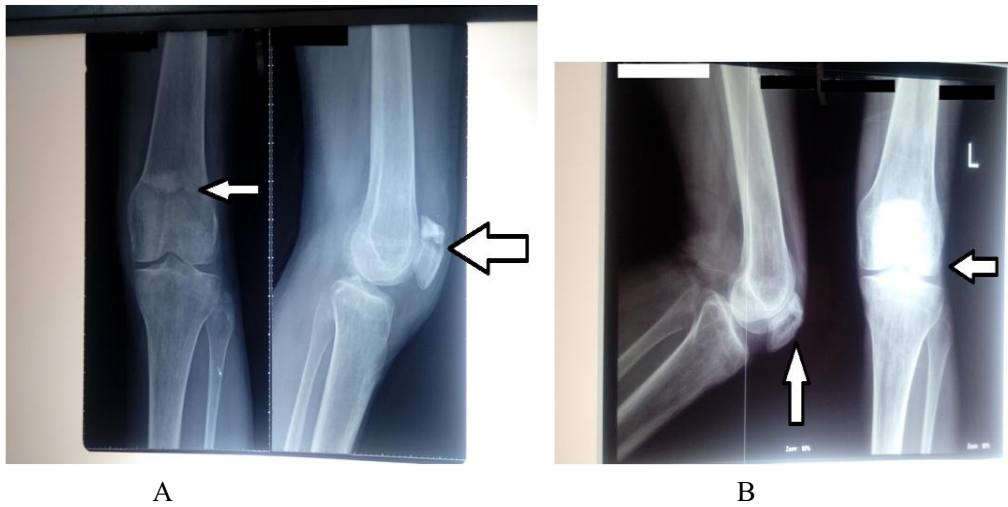


Figure 3 shows (A: x-ray of fracture of left patella before laser treatment and B: after the course of laser treatment)

The RUST is based on callus formation and visibility of fracture line at 4 cortices observed on Antero-posterior and lateral radiographs. Minimum score of 4 indicates no healing and maximum of 12 indicates a healed fracture, according to table (1).

Table (1) overview of radiographic union scale in tibial fracture (RUST).

Score per cortex	Callus	Fracture Line
1	absent	visible
2	Present	visible
3	present	invisible

5.2-Pain measurement

The fracture site of each participant was identified based on radiographs and physical examinations. Thereafter, the orthopedic surgeon measure the intensity of the participants' pain, and participants were asked to assess their pain by using a visual analog scale (VAS).The visual analogue scale consists of a 10 cm line anchored at one end by the label 'No pain' and at the other end 'Worst possible pain'. The patient marks on the line the spot for the pain intensity which is then measured (Dixon JS& Bird HA 1981).

5.3-Range of motion

Each joint above and below the fracture site was measured for range of motion performed with goniometer. The ranges of both joints were recorded before treatment, after 1 month and at the end of treatment. The measurements were performed by the same physical therapist.

5.4-Assessment of edema

We found that most of the Patients with delayed bone healing have significant edema at the fracture site, the physical therapist measured the girth of the edematous part before start of treatment and at the end of treatment.

6- Statics analysis and Result

This study comprise 33 patients with delayed and non-union bone fracture at different bone sites, all subject received average 24sessions of LLLT. The obtained result reveled average improvement of pain indicated by VAS assessment as 6.5 ± 1.9 (before treatment) 1.14 ± 1.7 (after treatment) table (2)
Callus formation assessment before treatment 3.63 ± 2.8 and after treatment 9.2 ± 3.5 table (2)

Table (2) Showed number of sessions, VAS and callus formation in pre and post treatment

	Minimum	Maximum	Mean	Std. Deviation
Number of sessions	12	50	24.19	8.696
VAS pain assessment before treatment	2	9	6.46	1.915
VAS pain assessment after treatment	0	6	1.14	1.715
Callus assessment before treatment	0	9	3.63	2.846
Callus assessment after treatment	0	12	9.20	3.517

The most frequent fracture sites area as follows (tibia, right scaphoid, and 5th metatarsal followed by scaphoid and rest of fractures as equal as shown in figure (4).

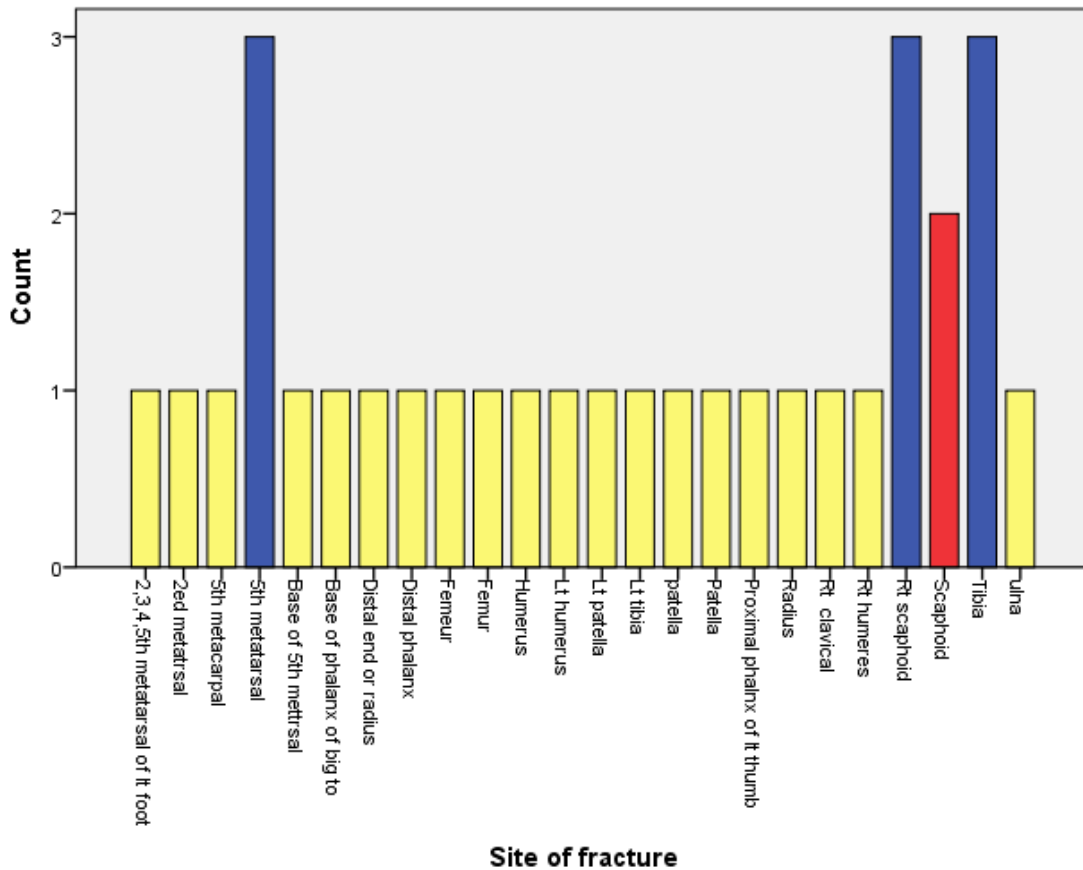


Figure (4) showed fracture sites area among study groups

Comparing edema fracture assessment before and after treatment, the obtained result showed higher significant difference as $p=0.00001$ as edema showed marked substantial decrease after treatment with LLLT figure (5).

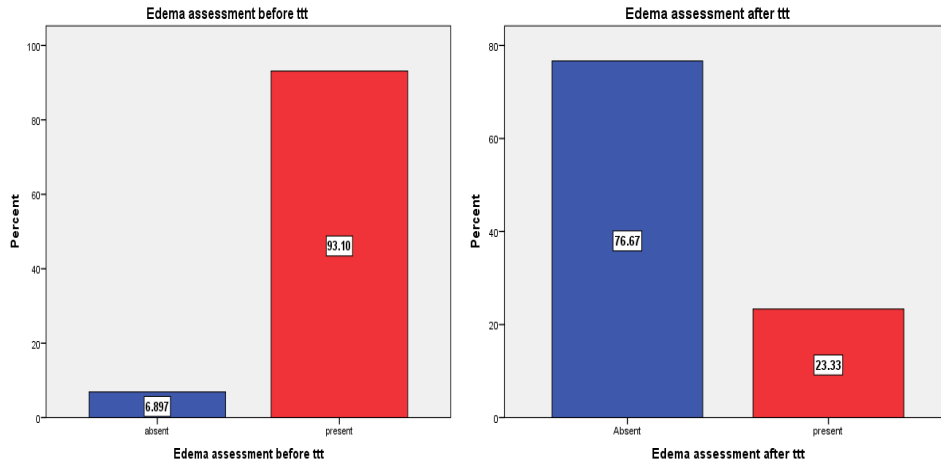


Figure (5) Showed comparison of edema fracture assessment before and after treatment

Table (3) show comparison between pre and post treatment for both VAS and callus formation assessment

Assessment	Mean	Std. Deviation	P value
VAS pain assessment before treatment	6.46	1.915	0.0001
VAS pain assessment after treatment	1.14	1.715	
Callus assessment before treatment	3.63	2.846	0.0001
Callus assessment after treatment	9.20	3.517	

*results were significant at $p \leq 0.05$

The obtained results of both VAS and callus formation showed higher significant difference between pre and post treatment $p=0.0001$ table (3), figure (6).

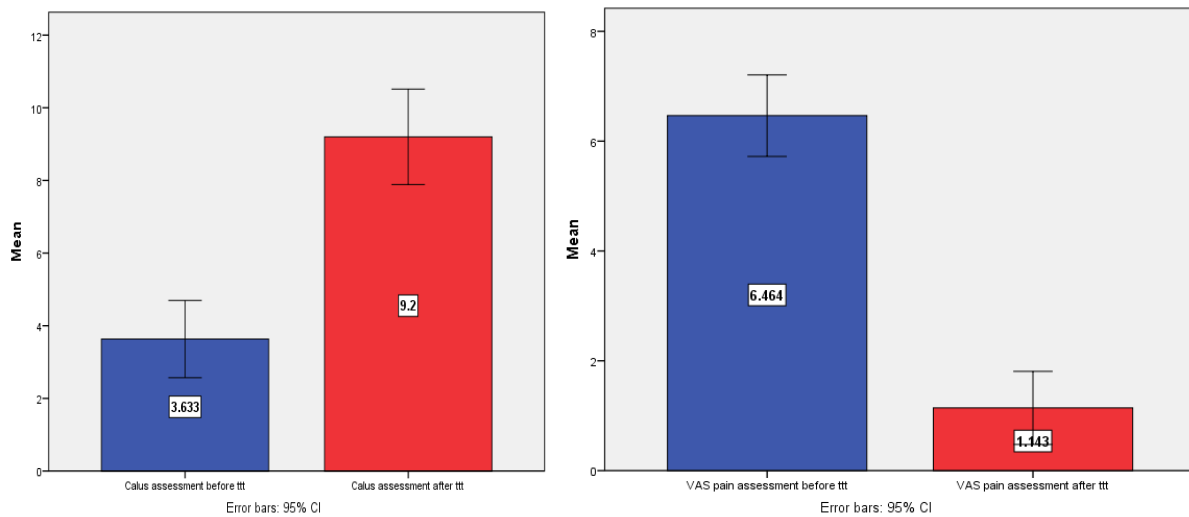


Figure (6) showed comparison of VAS in pre and post treatment assessment

Comparing VAS and callus formation regarding fracture site, only VAS showed significant difference as $p=0.03$ but callus formation did not differ for after treatment assessment. Regarding comparing post treatment results assessment for VAS and callus formation with number of sessions, both showed no significant difference as $p=0.597$ and 0.919 respectively. Regarding assessment of edema after treatment with sites of edema the obtained results showed non-significance difference between the edema sites as 87% showed improvement (absent) of edema versus 12.3% (present) as $p=0.188$ also for edema assessment after treatment with fracture site $p=0.118$.

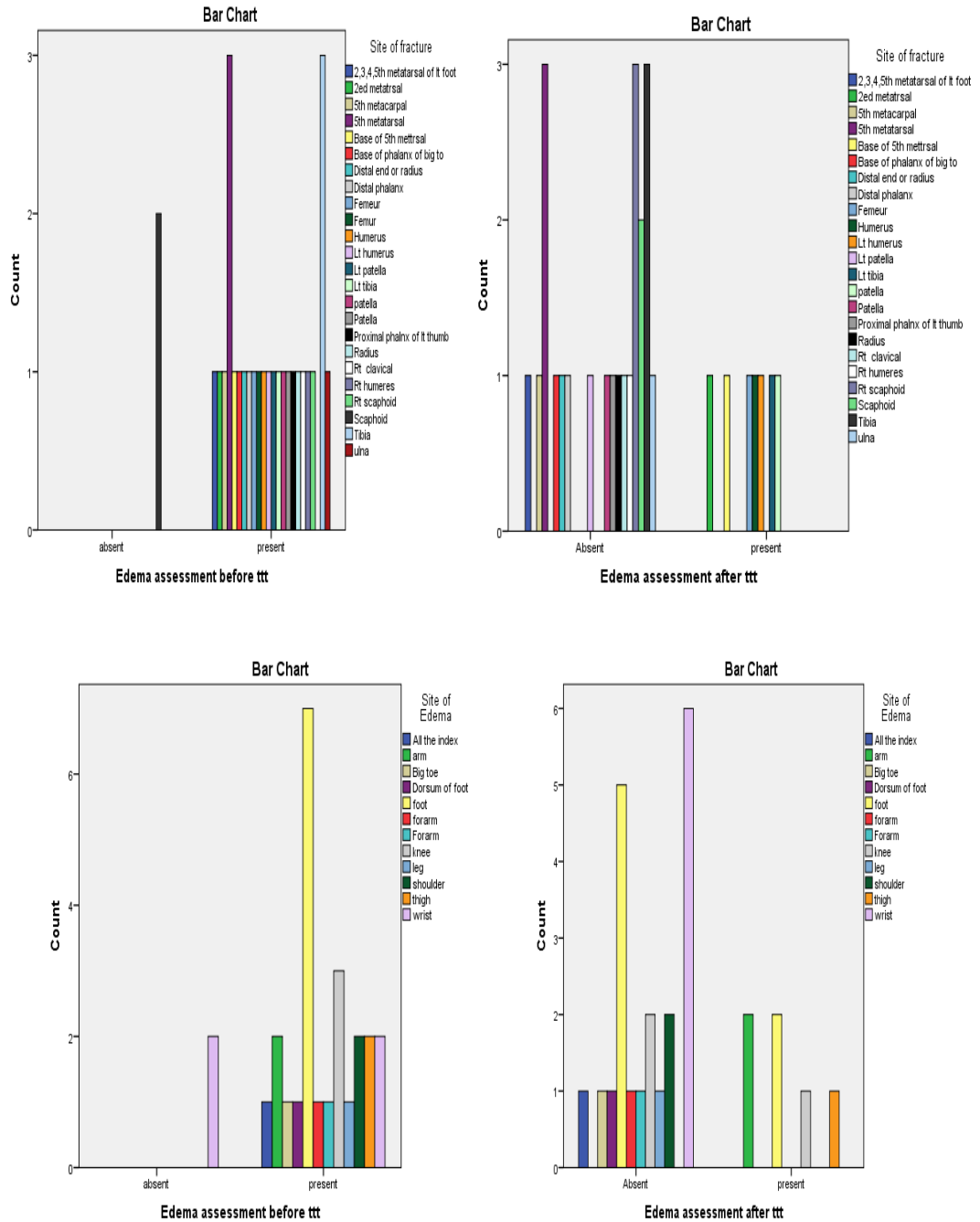


Fig (7) comparison between pre and post treatment for edema assessment as per edema and fracture sites

7. Discussion

Based on our philosophy to not to haste a normal physiological process that assumed to be happened as in fracture healing, we utilized LLLT for the management of delayed and non-union fracture which is not in agreement with the previous studies which utilized LLLT whether in-vivo or in-vetro in the acute phase of the healing of the fracture (**Ebrahimi et al., 2012**).

Previous studies reported that using LLLT in the management of fracture healing and prove that it is usefulness in enhancement of the activity of inflammatory and osteoblastic cells , To the best of our knowledge, our study is the first to investigate the effect of LLLT in delayed bone healing in human. In our study, we chose to use a LLLT in the infrared spectrum as to gain the advantage of its ability for more deeper penetration through the subcutaneous tissues to reach deeply to the bone which is in accordance with previous results of (**Liebert et al., 2008**).The photobiomodulation effect of LLLT is dependent on many factors including wavelength and the treatment dose, in our study we applied diode laser in form of GAALAS with a wavelength of 905 nm and treatment dose of 4 J/cm² over the delayed fractures which had significant improvements in fracture status with decrease in pain, edema and improved range of motion of the involved joints.

In respect to treatment parameters, there is no specific definite parameters in terms of (wavelength, frequency, power and energy density) ,which could determine the most effective treatment protocol for enhancement of bone healing, we utilized a high frequency with a low power infrared laser for the enhancement of fracture which is proven to have a beneficial effect in treatment of delayed bone fracture , which is not in agreement with other studies that addressed low frequency with a low power infrared laser for bone healing (**Ueda Y & Shimizu N.2001**). This issue confirms that body response to physical modalities such as laser is not dependent on parameters only but other physiologic and environmental issue could be addressed.

The beneficial effect of LLLT for treatment of delayed bone fracture could be attributed to the modulatory effect of inflammatory mediators presented in the fracture site, we think that the fracture site stuck in the inflammatory stage and did not progress to proliferative and remodeling stages of the normal healing process ,thus the use of LLLT to modulate the inflammatory cytokines and push into the reparative phases of bone healing was the main issue in the improvement in our study which may be explained be the result of (**Lee et al., 2018**) how concluded that LLLT with a dose of 8 J/cm² in form (GaAlAs laser, 660 nm) of has a modulatory effect of the inflammatory cytokines which lead to suppress of inflammatory stage. In another study by (**Nicolau et al., 2003**) used GaAlAs laser of 660 nm with a dose of 10 J/cm² to study the effect of LLLT on the activity of bone cells and found that the irradiated group had a greater surface of osteoblast and a more mineralization compared to the non irradiated group, the other interesting finding by (**Nicolau et al., 2003**),that there was an increase in the activity of osteoclast cells at the 5th day post-surgery in the irradiated group. We assume that the biological response of LLLT for enhancing the delayed fracture healing is one of the aforementioned mechanisms even that there is no definite suggested mechanism for explaining what really happened, further studies addressing additional investigations added to the use of clinical serologic marker to determine the healing of fracture could draw the way of what is really might be going on deep in the bone.

our study revealed that pain associated with delayed fractures was significantly reduced after LLLT even that patient has already stopped medication prior to the start of LLLT treatment and along the treatment time this has shown with a significant change in Visual analogues scale of all cases ,our results are in agreement with the result of other work of (**Nesioonpour et al., 2014**) who found that LLLT in form of combination of both Infrared and red spectrum (GaALAs, 808 nm and GaALInP, 650 nm) had significantly reduced fracture pain.

We found that when treating patient with delayed bone healing that the concurrent edema resolve with LLLT, most of the patient had resolved edema at the 1st month of laser treatment which is approved by other researches who used diode laser in form of GaAlAs at wavelength 820 nm and found significant decreased in edema in the laser treated group associated with RICE (rest ,ice, compression and elevation) more than the other groups who used RICE only or RICE with sham laser (Stergioulas, 2014). The reduction of edema associated with delayed fracture healing could explain the improvement in range of motion after LLLT treatment compared to before treatment, this improvement may be explained by the decrease of edema around the joint ,as joint swelling is considered to be one of the possible mechanisms that hinder the joint to move freely as explained by (Holm et al., 2010) ,who found a direct relationship between knee joint swelling postoperatively and the functional performance of the joint with that a swelling is might be the cause of decreased strength and range of motion.

With the frequent assessment, in treating patient with LLLT for delayed bone healing, it was found that the LLLT has beneficial effect on other conditions. Three patients had improve from chronic colonic disorders, five cases had acute wound in the contralateral limb, patients had noticed that increasing in the speed of healing of their wounds and eight patients had improved from chronic headache. The improved cases had informed that not to take any medications during the period of treatment. These result may suggest that LLLT has a systemic effect on other conditions which is in agreement with other studies which found that LLLT was effective in treatment of wounds that had directly irradiated with laser and the other wounds which were not irradiated in the same animal (Rodrigo et al.,2009).

8. Conclusions

LLLT has proven to be beneficial in the management of delayed and non-union fracture with improvement of pain threshold, decreased of associated swelling with pain relief, and improvements in range of motion of surrounding joint with no adverse effect provided that adequate patient selection has conducted. The clinical effects of LLLT on human bone healing have not been fully understood with Further studies are required to enhance our standing in the effect of LLLT for bone healing.

Acknowledgments: The authors of this article wish to express their deep gratitude to Dr. Mamdouh Elaraby, the Head of the Medical Sector of Elaraby Company and the General Manger of Elaraby International Hospital for his deep encouragement , support during the course of the research and comments on the earlier version of the manuscript. This acknowledgement is nothing for such esteemed person.

Author Disclosure Statement: No competing financial interests exist.

Conflicts of Interest: authors declare that there is no conflict of interest

References

1. Bahney, C. S., Diane, P., Iii, T. M., and Marcucio, R. S. 2015. The multifaceted role of the vasculature in endochondral fracture repair, 6(February), 1–10.
2. Dixon, J. S., and Bird, H. A. 1981. Reproducibility along a 10 cm vertical visual analogue scale. *Annals of the rheumatic diseases*, 40(1), 87–89
3. Ebrahimi, T., Moslemi, N., Rokn, A., Heidari, M., Nokhbatolfighahaie, H., and Fekrazad, R. 2012. The influence of low-intensity laser therapy on bone healing. *Journal of Dentistry (Tehran, Iran)*, 9(4), 238–48.
4. Griffin XL, Costa ML, Parsons N, Smith N. 2011, Electromagnetic field stimulation for treating delayed union or non-union of long bone fractures in adults. *Cochrane Database of Systematic Reviews Issue 4*. Art.
5. Holm, B., Kristensen, M. T., Bencke, J., Husted, H., Kehlet, H., B, A. H, Husted, H. 2010. Loss of Knee-Extension Strength Is Related to Knee Swelling. *YAPMR*, 91(11), 1770–1776.
6. Hui-ju, W., and Jiang, J. 2017. Therapeutic Outcomes of Low-Level Laser Therapy, (March 2014).
7. Karu T, Pyatibrat L, Kalendo G. 1995. Irradiation with He-Ne laser increases ATP level in cultivated in vitro. *J Photochem Photobiol*, 27, 219–223.
8. Kooistra, B. W., Dijkman, B. G., Busse, J. W., Sprague, S., Schemitsch, E. H., and Bhandari, M. 2010. The Radiographic Union Scale in Tibial Fractures : Reliability and Validity, 24(3), 81–86.
9. Lee, J., Chiang, M., Chen, P., and Ho, M. 2018. Anti-inflammatory effects of low-level laser therapy on human periodontal ligament cells : in vitro study, 469–477.
10. Liebert, M. A. 2005. Low-Level Laser Irradiation Promotes Proliferation and Differentiation of Human Osteoblasts in Vitro, 23(2), 161–166.
11. Liebert, M. A., Gerbi, M. E. M., Marques, P. D. A. M. C., Ph, D., Carvalho, C. M., and Santos, D. D. S. R. D. E. C. 2008. Infrared Laser Light Further Improves Bone Healing When Associated with Bone Morphogenic Proteins : An in Vivo Study in a Rodent Model, 26(1), 55–60.
12. Nesioonpour, S., Mokmeli, S., Vojdani, S., Mohtadi, A., Behaen, K., Moosavi, S., and Hojjati, S. 2014. The Effect of Low-Level Laser on Postoperative Pain After Tibial Fracture Surgery : A Double-Blind Controlled Randomized Clinical Trial, 4(3).
13. Nicolau, R. A., Jorgetti, AE. V., Rigau, AE. J., Pacheco, M. T. T., and Luciene, Æ. M. 2003. Effect of low-power GaAlAs laser (660 nm) on bone structure and cell activity : an experimental animal study, 89–94.
14. Phieffer LS, Goulet JA. 2006 Delayed unions of the tibia. *Journal of Bone and Joint Surgery - American Volume; Vol. 88*, issue 1:206–16.
15. Rodrigo, S. M., Cunha, A., Pozza, D. H., Blaya, D. S., and Moraes, J. F. 2009. Analysis of the Systemic Effect of Red and Infrared Laser Therapy on Wound Repair, 27(December), 929–935.
16. Shakouri, S. K., and Soleimanpour, J. 2010. Effect of low-level laser therapy on the fracture healing process, 73–77.
17. Stergioulas, A. 2014. Low-Level Laser Treatment Can Reduce Edema in Second Degree Ankle Sprains, (April 2004).
18. Tajali, S. B., Macdermid, J. C., Houghton, P., and Grewal, R. 2010. Effects of low power laser irradiation on bone healing in animals : a meta-analysis, 1–10.
19. Ueda Y, Shimizu N. 2001 Pulse irradiation of low-power laser stimulates bone nodule formation. *J Oral Sci*. Mar;43(1) 55-60..
20. Watanabe, Y., and Matsushita, T. 2010. Ultrasound for Fracture Healing : Current Evidence, 24(3), 56–61.
Yasuda I. 1953. Fundamental aspects of fracture treatment. *Journal of the Kyoto Medical Society*;4:395–406.